



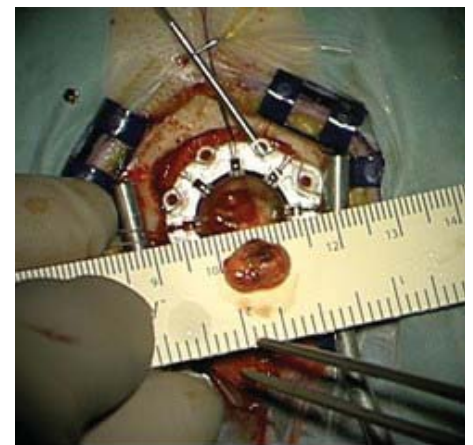
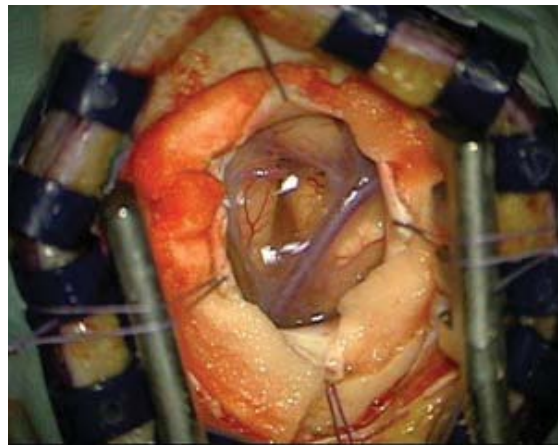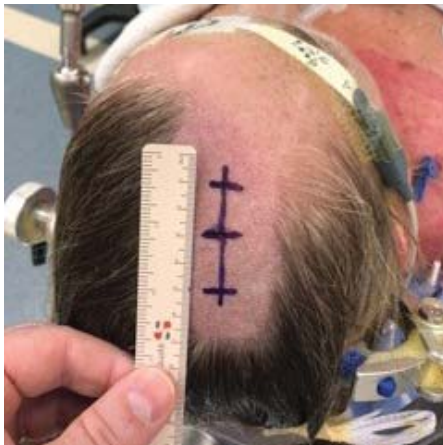
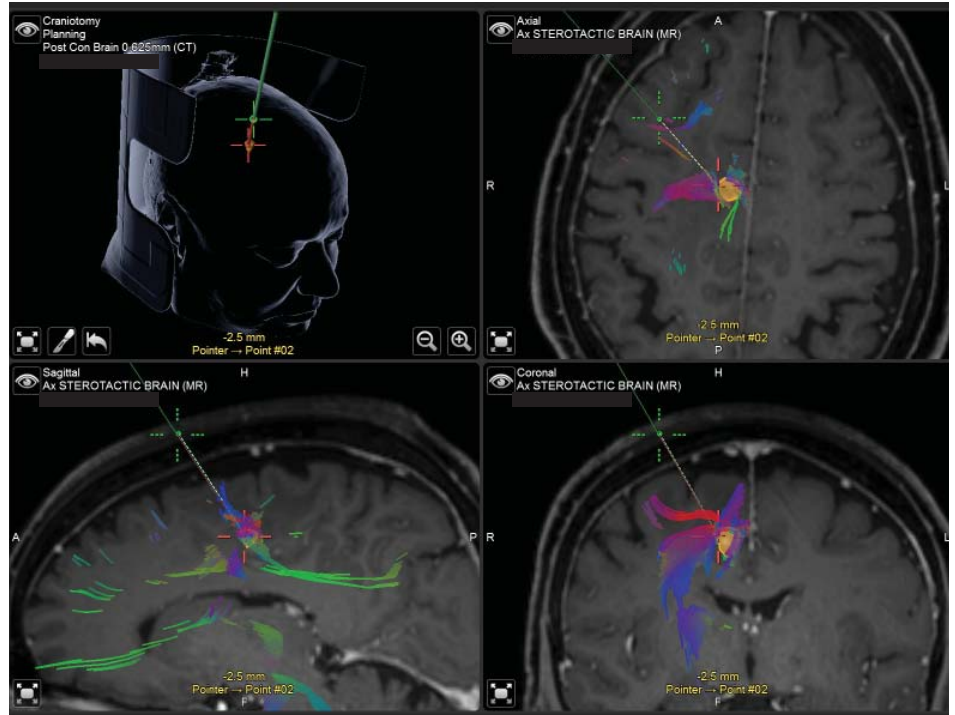
## INTERNATIONAL | Trans-Sulcal Surgical Approach SSG CASE REVIEW | Right Posterior Frontal Metastasis

### Clinical Presentation

The patient is a 78 year-old female with a remote history of lobular breast cancer with no history of metastasis. She is a heavy smoker. She presented with a one week history of headache and left upper limb and lower limb weakness, which improved following commencement of Dexamethasone. MRI showed a 12mm enhancing lesion in the right posterior frontal lobe. Her case was discussed in a multi-disciplinary tumor meeting. Stereotactic radiosurgery was considered; however, it was felt that surgical resection would be the preferred treatment as a tissue diagnosis was required to plan further systemic treatment. It was also felt that resecting the lesion in a minimally invasive fashion would remove the mass effect and relieve some of her deficits quickly.

### Surgical Management

Pre-operative DTI imaging was performed. Surgical approach was planned through the precentral sulcus running parallel to association fibers. Mannitol was not used. The first attempt at cannulating a tubular retractor resulted in bleeding from a sulcal vessel. Hemostasis was secured. **Re-cannulation provided direct access to the tumor and complete tumor resection was achieved.** Total operating time was 2 hours and 45 minutes; intra-dural operating time was 1 hour and 45 minutes.

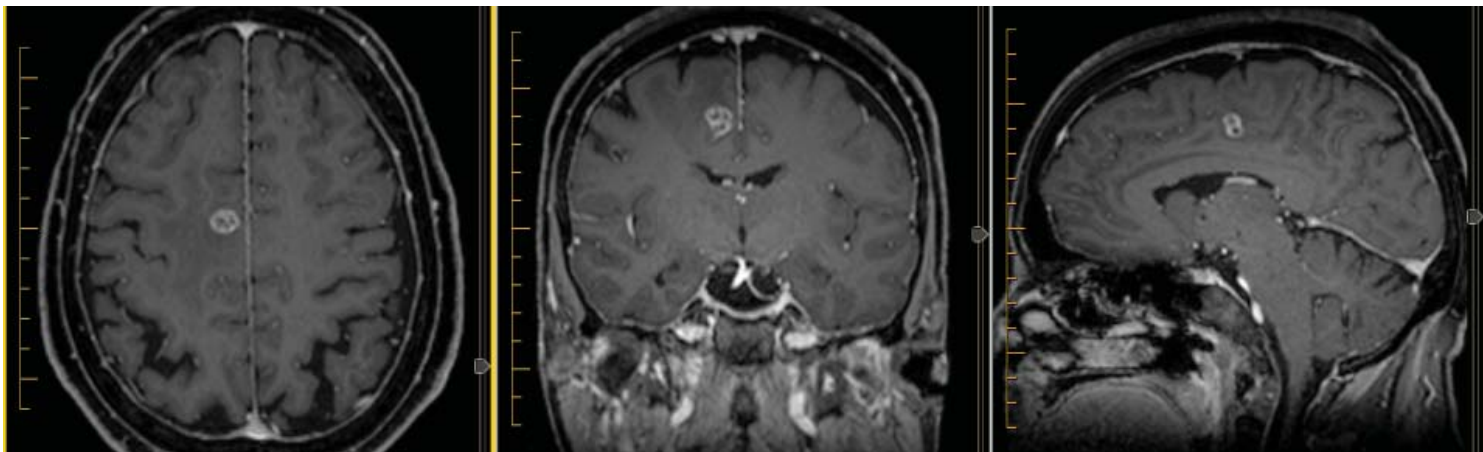


## Clinical Course & Outcomes

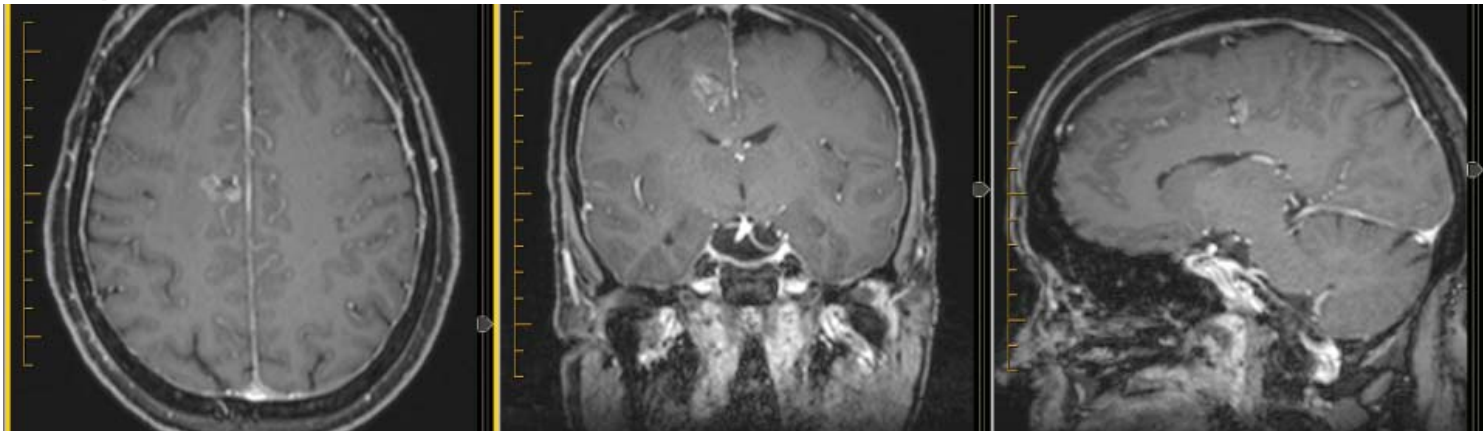
**Immediately post-operative the patient had normal power in her left side.** From an anesthetic perspective, the main difference was that Mannitol wasn't used. She did experience a transient decrease in spontaneous movements in her left hand and difficulty performing voluntary movements with the left hand. This was consistent with a post-operative supplementary motor area syndrome. **She was observed overnight in the ICU (standard practice in Australia) and was discharged to the ward the next day.** Her symptoms resolved over the course of one week in hospital with physical therapy for her left hand. Further in-patient rehab was not required.

Post-operative MRI confirmed complete resection of the tumor. Histopathology revealed a metastatic adenocarcinoma which is consistent with lung primary.

### Pre-Op MRI:



### Post-Op MRI (48 hours):



If you have a notable case review to share, please contact us at [info@SubcorticalSurgery.com](mailto:info@SubcorticalSurgery.com)