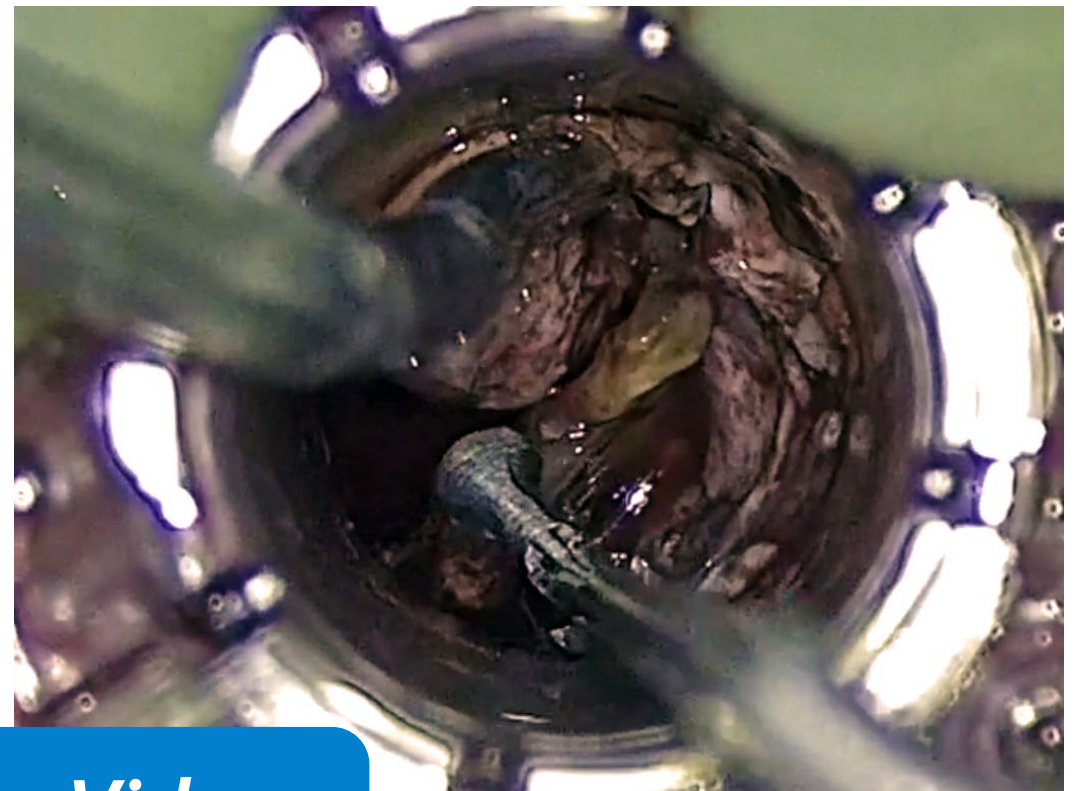
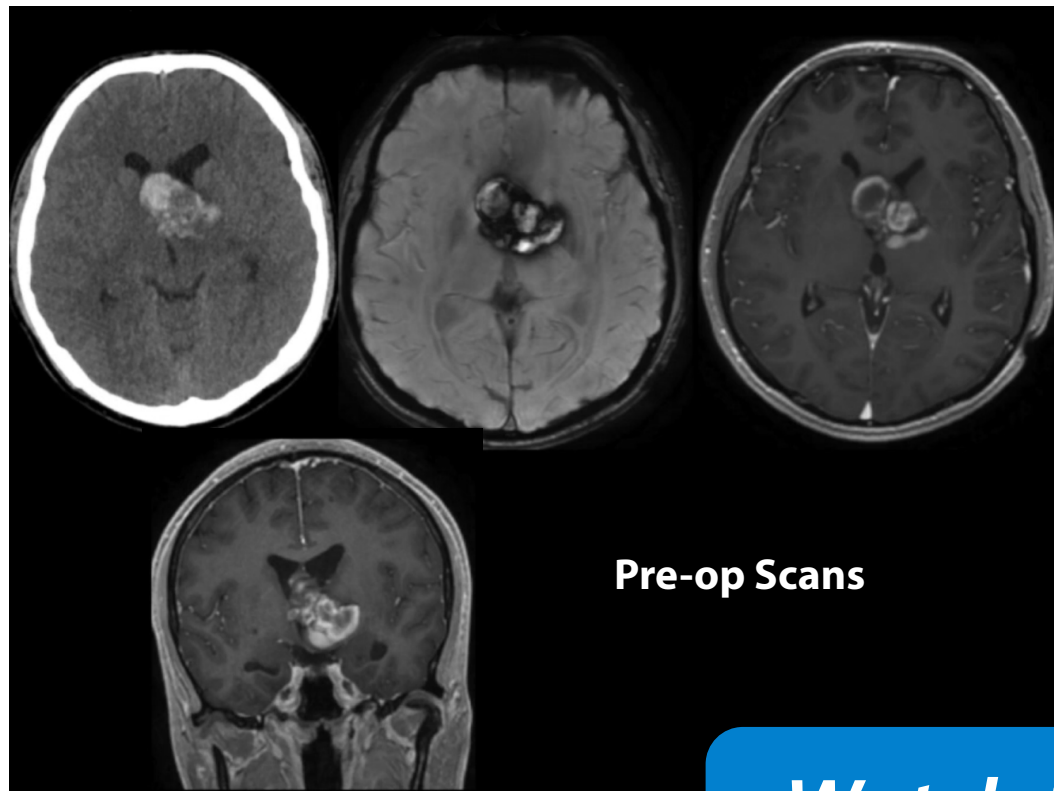


VIDEO CASE REVIEW

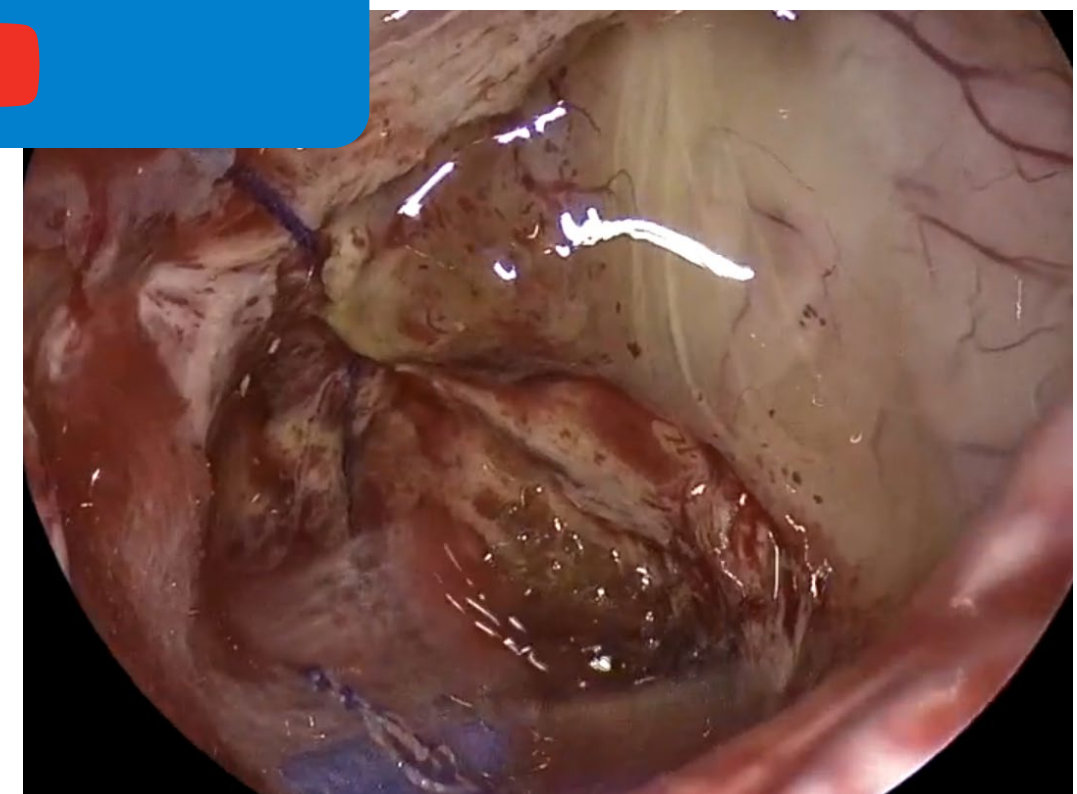
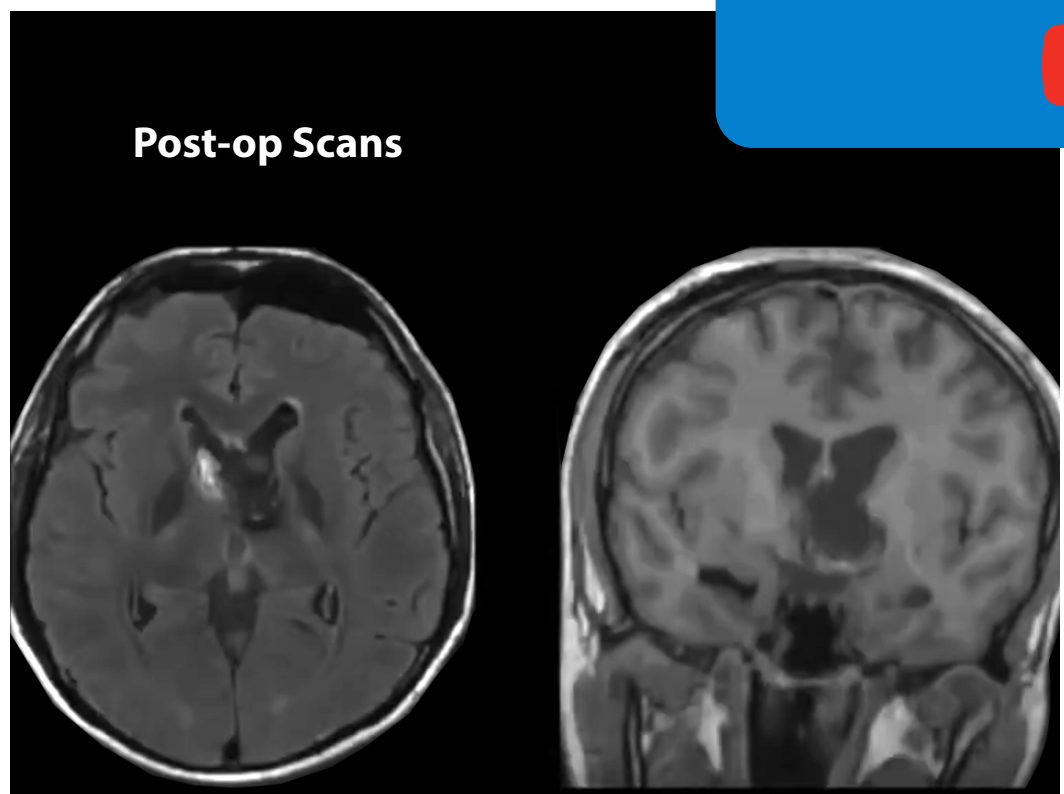
Exoscopic to Endoscopic (E2E) Channel-Based Transsulcal Resection of 3rd Ventricular Cavernous Malformation

Case performed by:

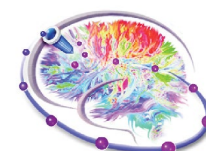Ben Strickland, Andrew Brunswick & Gabriel Zada at Keck School of Medicine of USC



[Watch the Video](#)



The details and associated images and/or video of this clinical case were used with permission by the surgeon and is for illustrative purposes only. 2020.



**SUBCORTICAL
SURGERY GROUP**